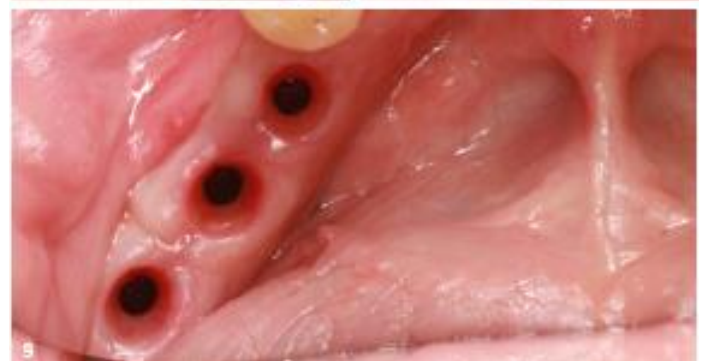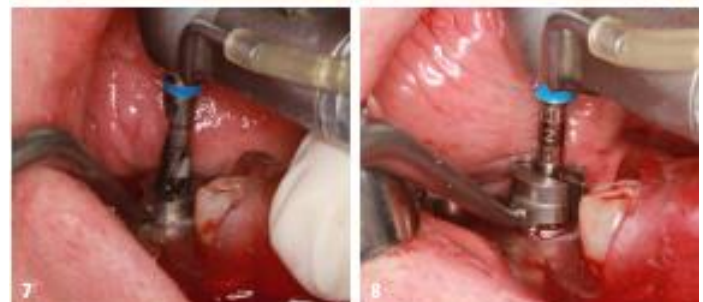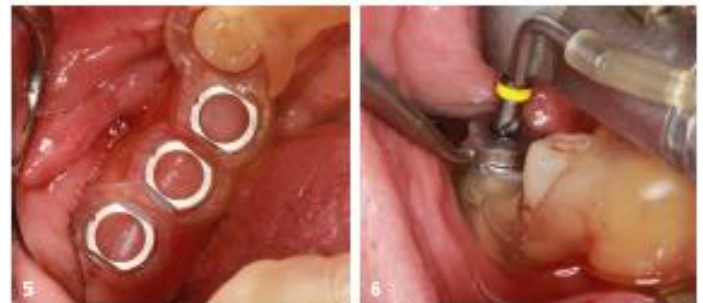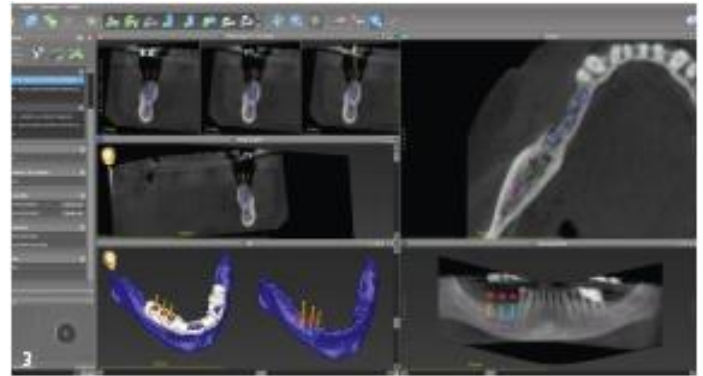


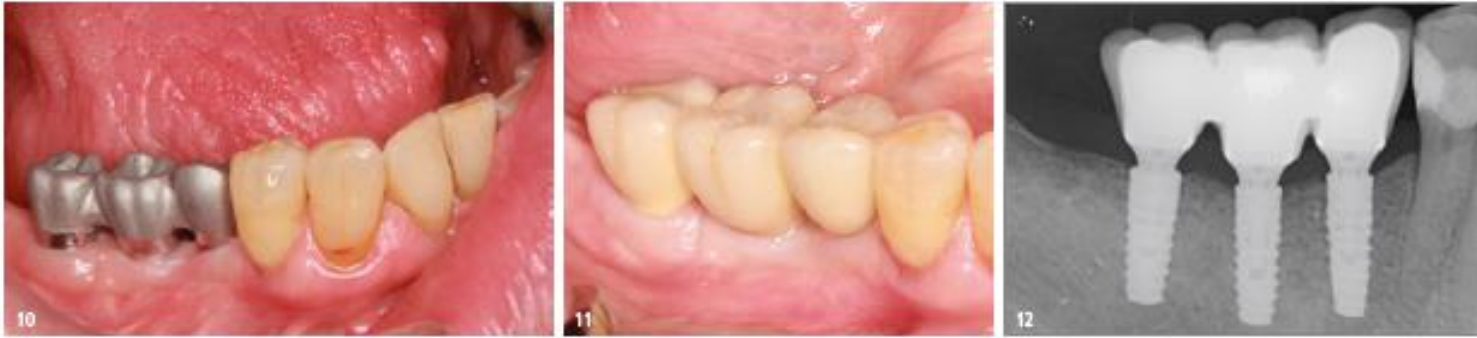Planning of the implants and the surgical template, taking into account the available bone and suitable restoration.

- Fig. 4: Instrument set for LASAK BioniQ guided surgery with surgical templates.
- Fig. 5: The tooth-supported surgical template fits well in the mouth.
- Fig. : The preparation was started with the S2.9 guided drill of the smallest diameter ...
- Fig. : ... and then continued with the drill for the corresponding implant diameter.
- Fig. : Finally, the guided threadformer was used.
- Fig. 9: The situation after uncovering the implants after three months.

Cooperation between the dentist and the dental technician is a must when planning implantological treatment. Imaging procedures and computer technologies make it possible to plan and design the resulting prosthetic treatment optimally, or at least almost optimally. Part of this collaboration also involves the design of the surgical template and, thus, of the implant positions too. The use of a surgical template is no substitute, however, for the dentist's own skill and experience in Implantology. Especially during the procedure, situations or complications may occur in which the surgical template has to be removed (e.g., template breakage, restricted mouth opening, etc.), and the rest of the procedure will have to proceed using freehand technique according to the standard protocol without using the surgical template. Based on practical experience, it can be concluded that navigated implant placement should be performed by experienced implantologists to ensure that the treatment is functionally and aesthetically satisfactory in the long term – without complications and the need for correction. The current trend in navigated implantology is the placement of implants using surgical templates (guided surgery – static navigation). This should ensure safe and relatively accurate implant placement, i.e., determine the exact position of the implant, the diameter, the correct inclination, and the depth of the implant bed, and create suitable conditions for a provisional or definitive prosthetic restoration. The use of active navigation (dynamic), in which the operation is performed without a surgical template and the progress is checked visually on monitors, is currently less common. One of the limiting factors is the relatively high purchase price of these systems. The principle of dynamic navigation is that an optical tracking system shows the immediate position of the drill on a screen (intra-bone GPS) thanks to markers placed in the surgical area and hand piece. The available studies evaluating the deviations between the planned and actual implant position using the surgical template, as well as our experience, show that there are no significant differences in the accuracy of the implant position when using the guided surgery sets of the different implant systems.





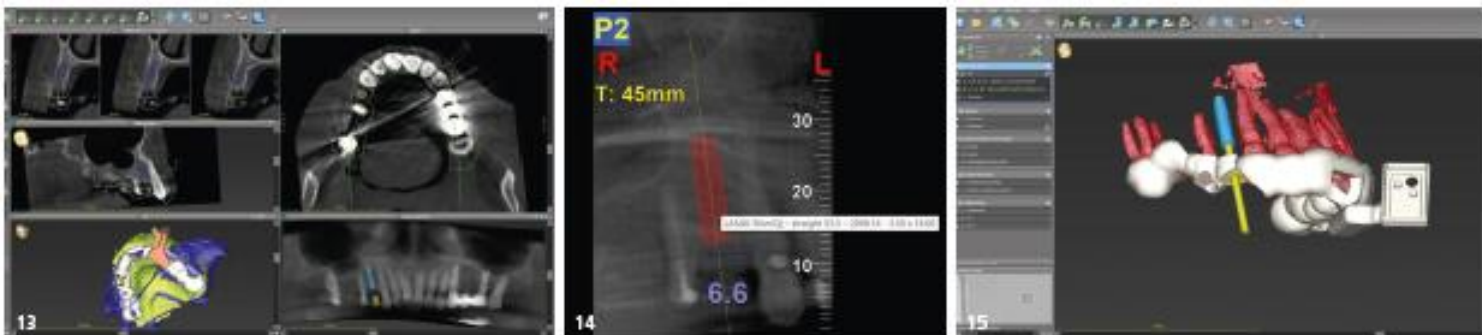There are also no significant differences in cases where guided pilot drilling or fully guided surgery was performed in our clinic. However, user-friendliness plays an important role, i.e., how user-friendly the work with the given set or system is for the dentist and how "pleasant" the patient perceives the treatment with the given set or system being used. For example, the length of guided countersinks or taps can be a problem in some systems when used in posterior areas or when the mouth opening is limited (Fig. 1). In these cases, it is necessary to perform the implantation with countersinks or taps from the conventional implantation set, which are usually shorter. Differences from the surgeon's point of view in terms of user-friendliness are also evident in the use of different types of drill guides for different drill diameters, e.g., drill handles that require fixation in the template by the hand of the surgeon or assistant or self-locking guide spoons that do not require fixation (assistance). Systems that do not use drill guides and which have a uniform diameter of the upper part of the drill that corresponds to the diameter of the guide hole in the surgical template, and which is used to guide the drill must have drills for each diameter and implant length. Here, the implant bed preparation must first be carried out with an initial drill, which has a shortened working length that allows the initial drill to be guided

using the entire height of the guide hole. Only then can the preparation be carried out with drills of a working length corresponding to the length and diameter of the inserted implant (Fig. 2a-c).

The advantage of some guided surgery sets is that they can be used for both guided pilot drilling and for fully guided surgery. This allows the dentist to select an individual approach and the best method for the patient to achieve an optimal treatment result. In some borderline situations, it is also possible to use a combination of guided surgery and dynamic navigation. It, therefore, depends on the dentist's experience and capabilities in allowing them to choose the optimal method of guided/navigated implant placement. In the following two patient cases, an implant system (LASAK BioniQ) is used for guided surgery. This can be used for guided pilot drilling and fully guided surgery as well as in combination with a system for dynamic navigation.

Case 1: Fully guided implantation

A 76-year-old patient, healthy and a non-smoker, presented himself to our practice for the treatment of a unilaterally shortened dental arch in the right mandible. He requested a fixed implant-supported denture.



Case 1

Fig. 10: The superstructure fits correctly.

Fig. 11: The final dental prosthesis.

Fig. 12: The control X-ray after the fitting of the dental prosthesis.

Case 2

Fig. 13: A dental bridge and an implant-supported bonded dental crown were planned.

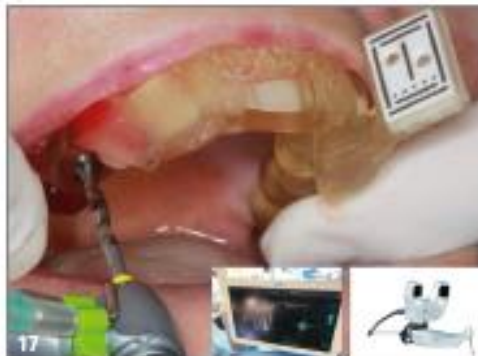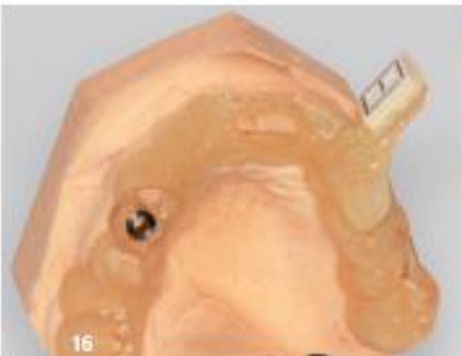
Fig. 14: The use of a 14 mm long LASAK BioniQ implant with a diameter of 3.5 mm was planned for Region 14.

Fig. 15: A combined surgical template, which also contains the holder for the dynamic navigation marker, was designed...

Fig. 16: ... and produced using a 3D printer.

Fig. 17: The preparation began with the S2.9 guided drill under the guidance of the DENACAM dynamic navigation system.

We made a CBCT scan of the mandible and then matched it with the model scan using coDiagnostiX software (Dental Wings). Based on the measurement of the bone volume, the placement of the following implants was planned in these regions: at 45 and 46, always using a 10 mm long implant with a diameter of 3.5 mm (LASAK BioniQ Straight) and at 47 an equally long implant with a diameter of 4.0 mm (LASAK BioniQ Tapered; Fig. 3). At the same time, the prosthetic restoration was planned using a fixed screw-retained metal-ceramic dental bridge. The designed tooth-supported surgical template was produced using 3D printing. An instrument set for guided surgery (LASAK BioniQ) was used for the implant placement (Fig. 4). After rehearsing the exact fitting of the surgical template in the mouth, the implants were placed in the planned positions (Fig. 5). In accordance with the surgical protocol, the S2.9 guided drill with the required length and an S2.9 drill guide (with the same colour strip) of the smallest diameter of 2.3 mm (Fig. 6) were used. Then the treatment was continued with the drills and the drill guides for the appropriate implant diameter (Fig. 7). The preparation was completed with the use of guided countersinks and taps with C-guides (Fig. 8). The implant placement was performed after the removal of the surgical template to avoid contact between the implant surface and the guide sleeve. After three months, the implants were exposed, and the impression was taken (Fig. 9). After the trial of the superstructure, the final dental prosthesis (Fig. 10-12) was screwed into place.



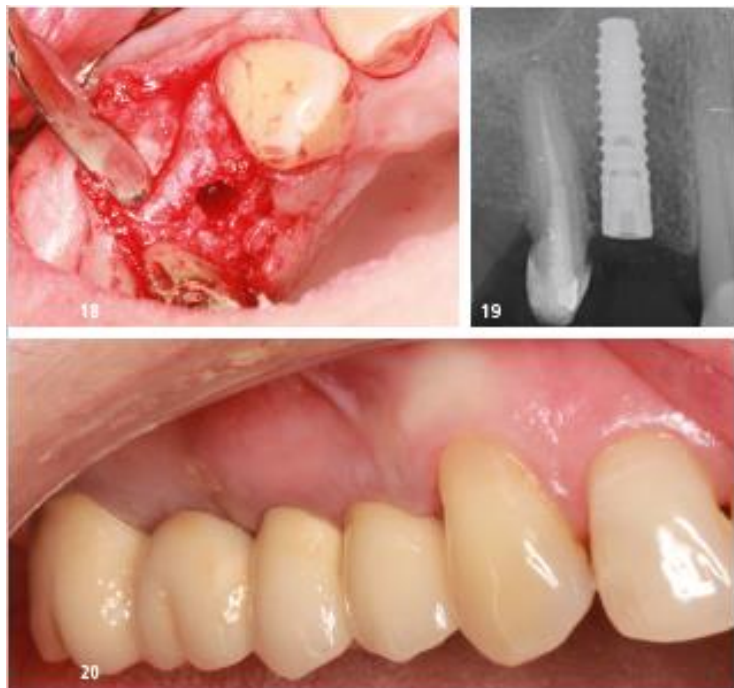
Case 2: Implantation with guided pilot drilling in combination with dynamic navigation

A 65-year-old female patient, healthy and a non-smoker, presented herself to our practice. It was necessary to remove an unsatisfactory fixed restoration supported by teeth 17, 15 and 14 and to extract tooth 14. Teeth 17 and 15 were treated endodontically. A CBCT scan of the maxilla was made and then matched with the model scan using coDiagnostiX software. Based on the measurement of the bone volume, a 14 mm long implant with a diameter of 3.5 mm (LASAK BioniQ Straight) was planned for region 14. A fixed metal-ceramic bridge on teeth 17–15 and a metal-ceramic implant-supported bonded dental crown (Fig. 13) were designed. After considering the clinical situation and the available options, a combination of guided pilot drilling and dynamic navigation was adopted. To make the implant placement as accurate as possible (given the limited bone available as well as the implant length of 14 mm) and to avoid the nearby root of the neighbouring tooth, a combined surgical template was designed. The teeth-supported template contained a guide sleeve for the guided pilot drilling and a holder for the dynamic navigation marker. The template was made on a 3D printer (Figs. 15 and 16). The implant bed preparation was started using the surgical template with the instrument set for guided pilot drilling (LASAK BioniQ). Subsequently, it was completed with the instruments according to the

protocol of the BioniQ system using the system for dynamic navigation (Denacam, mininavident; Fig. 17–20). This made it possible to check the exact compliance of the planned implant position on the screen.

Summary

Patients expect an ideal functional and aesthetic result from implantological treatment that is stable and sustainable in the long term. In most cases, today's digital technologies (digital workflow) make this possible and easier. Assuming that the position of the implant should be secondary to the prosthetics, it is important to be able to place the implant as accurately as possible in the previously planned position. Systems for both guided surgery and dynamic navigation are available. The currently most commonly used guided surgery systems (using surgical templates) ensure safe and relatively accurate implantation. When using the surgical template, not only the implant positions but also the entire course of treatment must be planned correctly. The dentist must decide, based on an assessment of the clinical situation of each patient, whether to perform guided pilot drilling, fully guided surgery, or dynamic navigation, or whether to, first, ensure that there are suitable conditions for implant placement, e.g., by hard or soft tissue augmentation. This is the only way to achieve the desired successful outcome.



Case 2

- Fig. 18: The implant was inserted after removing the template.
- Fig. 19: X-ray control image after the implantation. The implant was inserted as planned.
- Fig. 20: The final result after placing a fixed dental bridge on teeth 17-15 and an implant-supported dental crown on tooth 14.

Contact details



Dr. Jiri Hrkal
 HDC Kladno Private practice for dentistry
 Slanska 1525
 272 01 Kladno
 Czech Republic